The Spectrum of Retinal Imaging

Timothy J. Bennett, CRA, FOPS, OCT-*C*
Penn State Eye Center
Hershey, PA

PennState Health
Milton S. Hershey Medical Center

Disclosures

- No financial or proprietary interest related to the subject matter of this presentation.

PennState Health
Milton S. Hershey Medical Center

The Spectrum of Retinal Imaging

- Fundus Photography
- Monochromatic Photography
- Fluorescein Angiography
- ICG Angiography
- Scanning Laser Ophthalmoscopy
- Fundus Autofluorescence
- Optical Coherence Tomography

PennState Health
Milton S. Hershey Medical Center

The Spectrum of Retinal Imaging

- Retinal imaging devices utilize different portions of the electromagnetic spectrum.
- Wavelength is the physical distance between the crests of energy waves in the spectrum. (expressed in nanometers)

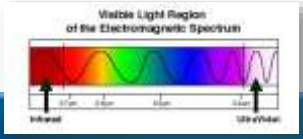

PennState Health
Milton S. Hershey Medical Center

Fundus Photography

- Documentation
- Telemedicine/Retina Screening

PennState Health
Milton S. Hershey Medical Center

Fundus Photography

PennState Health
Milton S. Hershey Medical Center

Serial Fundus Photography

PennState Health
Milton S. Hershey Medical Center

Fundus Photography

- Fundus photographs are often used as a reference to assist in interpretation of other diagnostic imaging procedures such as fluorescein angiography.

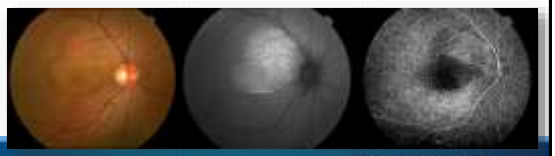

PennState Health
Milton S. Hershey Medical Center

Fundus Camera Illumination

- The optical system of the fundus camera projects a ring of light from the internal strobe axially through the dilated pupil.
- The ring shape allows a separation of the outgoing and incoming illumination.

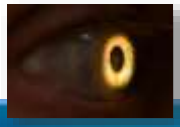

PennState Health
Milton S. Hershey Medical Center

Fundus Cameras

- Traditional (mydriatic)
  - Requires pharmacologic dilation
- Non mydriatic
  - Relies on physiologic dilation in a darkened environment
  - Results are often better WITH pharmacologic dilation

PennState Health
Milton S. Hershey Medical Center

Traditional Fundus Camera

- Requires pharmacologic dilation
- Variable magnification settings
- Best for peripheral imaging
- Easier to shoot stereo photos
- Required for many clinical trials

PennState Health
Milton S. Hershey Medical Center

Variable Magnification

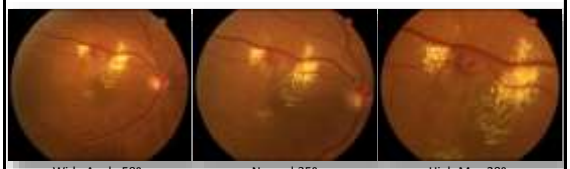

PennState Health
Milton S. Hershey Medical Center

Focus

- Optics of patient's eye.
- Properly set eyepiece.
- Focus control.
- Auxiliary lens for high-plus or high-minus eyes.
- Both the reticle and the retina need to be sharp at the same time.

Focus: Setting the Eyepiece

- Ignore the eyepiece numbers, but pay attention to the crosshairs and retina.

Focus

- Rock focus knob until image is sharp.
- Use myopic or astigmatic control if needed.
- Use green filter to increase contrast while focusing.

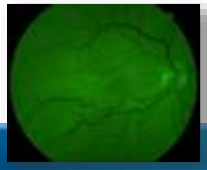

Non-Mydriatic Fundus Camera

- User-friendly system designed with an infrared video focusing system that promotes physiologic dilation in a darkened room.

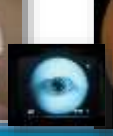

Dilation

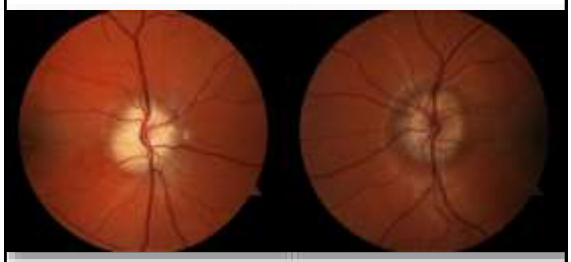

Monochromatic Fundus Photography

- The practice of imaging the ocular fundus with monochromatic illumination to enhance visibility of various fundus structures or pathologies.

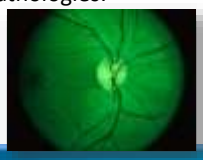

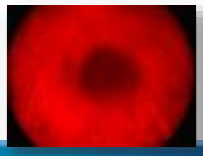

Monochromatic Fundus Photography

- The practice of imaging the ocular fundus with monochromatic illumination to enhance visibility of various fundus structures or pathologies.

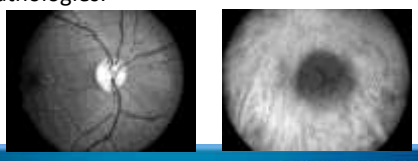

PennState Health
Milton S. Hershey Medical Center

Photographic Principles

- The use of contrast filters to alter subject tones in black-and-white photography.
- The increased scattering of light at shorter wavelengths.

PennState Health
Milton S. Hershey Medical Center

Contrast Filters

- Alter the tonal rendition of different subject colors by introducing brightness differences between colors that would normally reproduce as similar tones of gray.

PennState Health
Milton S. Hershey Medical Center



Fundus Structures

- Transparent
- Translucent
- Opaque

PennState Health
Milton S. Hershey Medical Center

Short (Blue/Cyan) Wavelengths

- Anterior translucent scattering structures

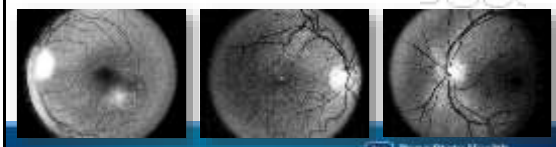

PennState Health
Milton S. Hershey Medical Center

Medium (Green) Wavelengths

- Retinal vasculature
- Hemorrhages
- Drusen
- Exudates



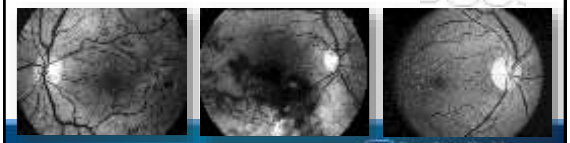

PennState Health
Milton S. Hershey Medical Center

Long (Red) Wavelengths

- RPE disturbances
- Choroidal ruptures
- Choroidal nevi
- Melanomas

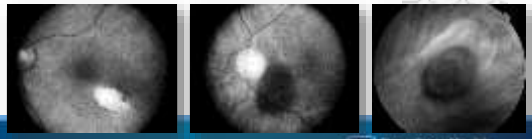

PennState Health
Milton S. Hershey Medical Center

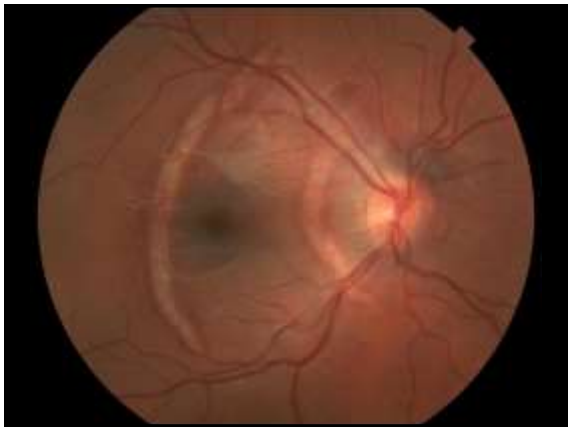

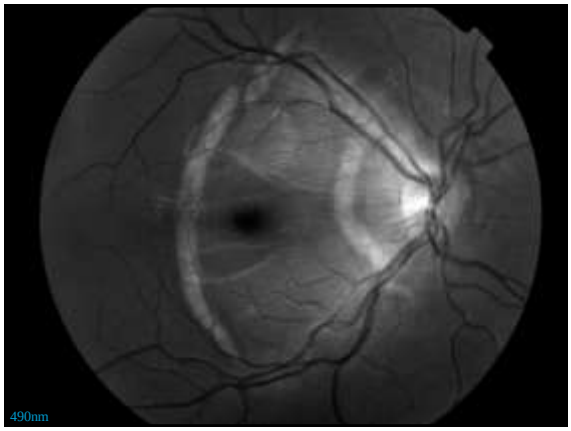

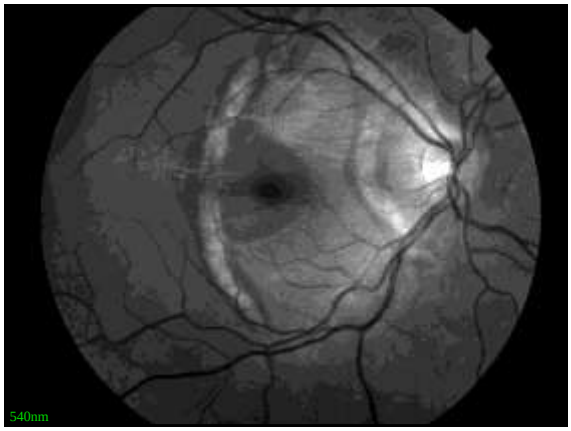

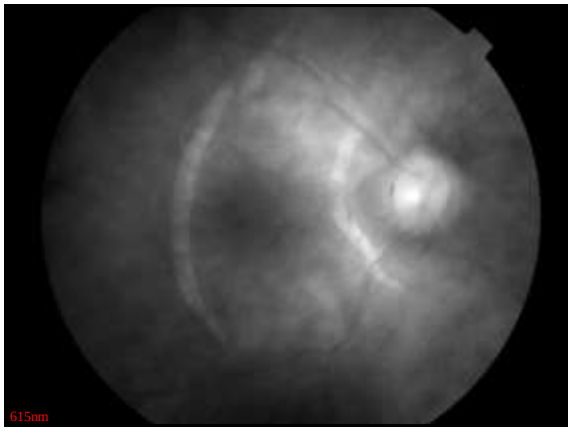

Common Use: Pre-IVFA "Red Free"

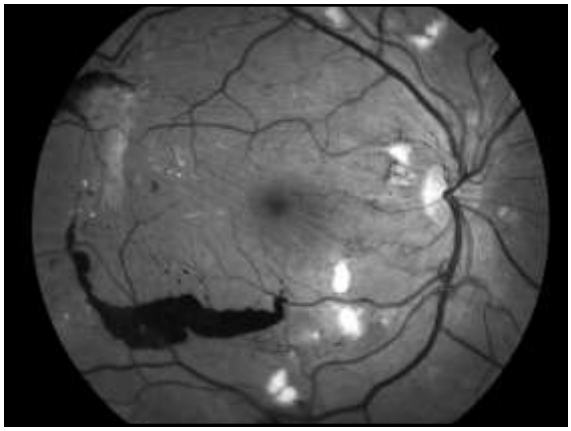

Tips for Fundus Photography

- Set the camera eyepiece correctly
  - Ignore the numbers
  - Relax accommodation to distance.
- Use green filter to focus on vessels or with photophobic pt.
- Maintain consistent technique from visit to visit with serial imaging.
- Facilitate best possible dilation.

Fluorescence Imaging

- Fluorescein angiography (retinal vasculature)
- ICG angiography (choroidal vasculature)
- Fundus autofluorescence (RPE)

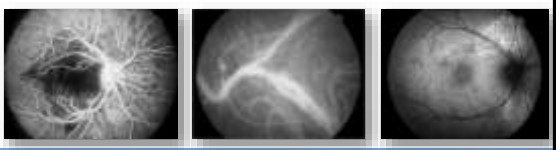

Fluorescein Angiography

Fluorescein Sodium

- Fluorescein sodium is a fluorescent dye synthesized from petroleum derivatives resorcinol and phthalic anhydride.
- Synthesized by Adolf Baeyer in 1871.
- Baeyer received the Nobel Prize in 1905.

Fluorescein Sodium

- Absorbs blue light, with peak absorption and excitation occurring at wavelengths between 465-490nm.
- Fluorescence occurs at the yellow-green wavelengths of 520 to 530nm.



PennState Health Milton S. Hershey Medical Center

"More Uses Than Duct Tape"

- Industrial uses:
  - Track/measure water flow dynamics
  - Track hazardous spill dispersion patterns
  - Identify point source of pollutants
  - Search and rescue marker
  - Detect obstructions or leaks in plumbing/sewage

PennState Health Milton S. Hershey Medical Center

"More Uses Than Duct Tape"

- Medical uses:
  - Intra-operative blood flow in surgical resections
  - Monitor chemotherapy in isolated limb perfusion
  - Intra-operative predictor of intestinal viability
  - Indicator of perfusion in gangrene or severe burns

PennState Health Milton S. Hershey Medical Center

"More Uses Than Duct Tape"

- Ophthalmic uses:
  - Applanation tonometry
  - Vital stain for ocular surface disorders
  - Nasolacrimal duct obstructions
  - Seidel test for corneal wound leaks



PennState Health Milton S. Hershey Medical Center

Fluorescein Sodium

- In angiography we use the water-soluble sodium salt of fluorescein.
- Maximum fluorescence occurs with a ph of 8 to 9.8.
- 500mg administered as a bolus injection, into the antecubital vein.

PennState Health Milton S. Hershey Medical Center

Fluorescein Angiography

- First performed by Novotny & Alvis in 1959.
- Can be captured with a fundus camera equipped with exciter/barrier filters or a confocal scanning laser ophthalmoscope.

PennState Health Milton S. Hershey Medical Center

Exciter and Barrier Filters





PennState Health
Milton S. Hershey Medical Center

Color - Grayscale

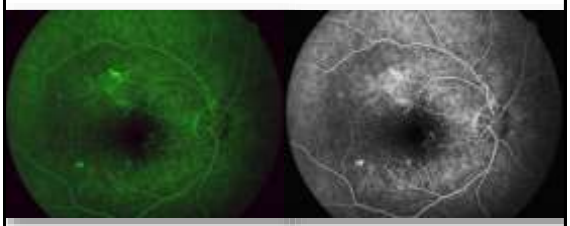

PennState Health
Milton S. Hershey Medical Center

Phases of an IVFA

- Early: First 45-60 seconds
- Mid: 2-4 minutes
- Late: 7-10 minutes

PennState Health
Milton S. Hershey Medical Center

Sequencing

- The arm-to-retina circulation time varies, but in a normal patient takes 10-12 seconds.
- Rapid sequence photography begins before the dye is visible.
- Images are routinely captured at a rate of 1 fps until maximum fluorescence occurs.
- During this dynamic early phase only one eye can be captured.

PennState Health
Milton S. Hershey Medical Center

Timed Sequence: Tells a Story

1 minute 3 minutes 7 minutes

PennState Health
Milton S. Hershey Medical Center

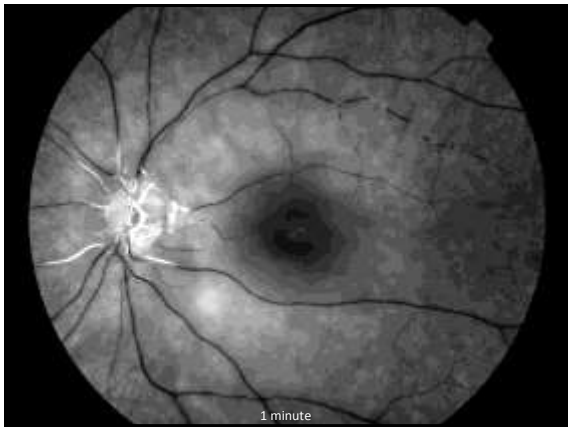

1 minute

Diagnostic Uses

- Diabetic retinopathy
- ARMD
- SRNVM from other causes
- CRVO
- BRVO
- Central serous chorioretinopathy
- Cystoid macular edema
- Hereditary dystrophies
- CRAO
- BRAO
- Retinal arterial macroaneurysms
- Pattern dystrophies of the RPE
- Choroidal tumors
- Hypertensive retinopathy
- Chorioretinal inflammatory conditions

PennState Health
Milton S. Hershey Medical Center

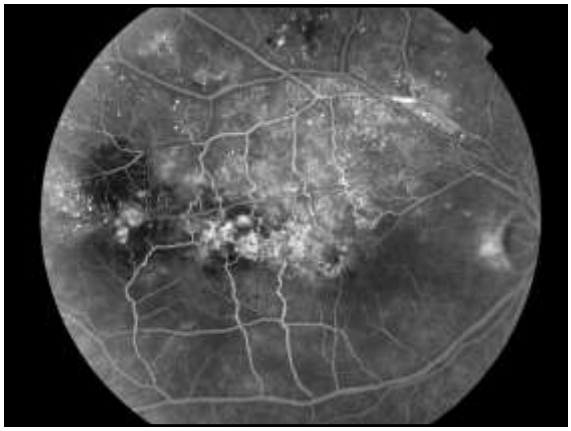

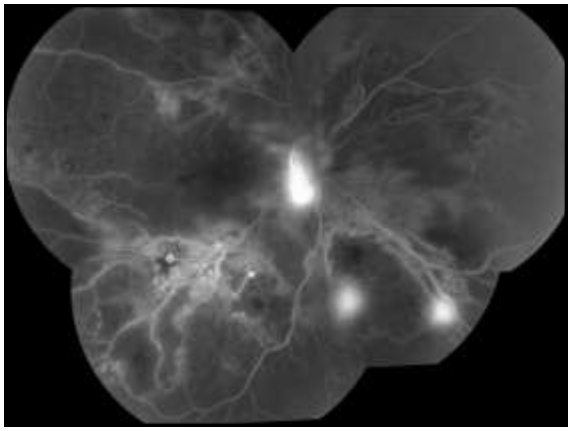

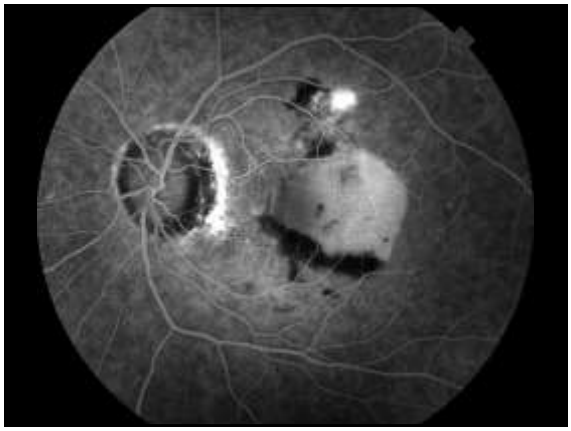

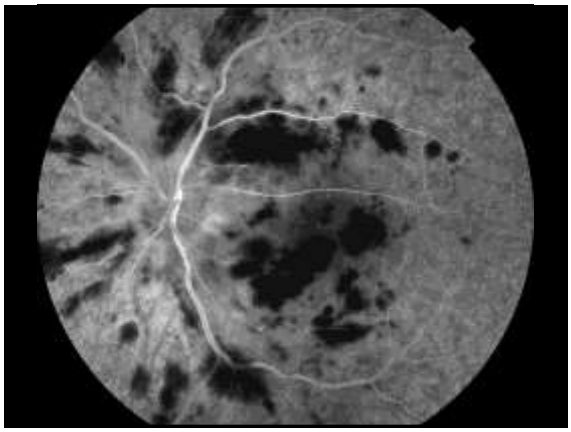

Side Effects

- Discoloration of the urine for 24 to 36 hours.
- Slight yellow skin discoloration that fades within a few hours.
- Nursing mothers should be cautioned that fluorescein is also excreted in human milk.

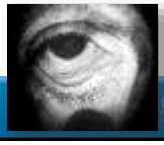

PennState Health
Milton S. Hershey Medical Center

Complications and Adverse Reactions

- Extravasation of dye
- Transient nausea
- Vomiting
- Pruritis
- Urticaria
- Bronchospasm
- Laryngeal edema
- Anaphylaxis
- Hypotension
- Syncope
- Seizures
- Myocardial infarction
- Cardiac arrest

PennState Health
Milton S. Hershey Medical Center

Tips for IVFA

- Center the illuminating beam of the fundus camera within the dilated pupil and pre-focus on area of interest before starting transit.
- Start timer at the beginning of the injection & take second frame when injection is complete.
- Begin rapid sequence imaging before dye is visible.
- Capture images at a rate of one frame per second until maximum fluorescence occurs.
- “Tell a story” with representative frames from all 3 phases.

PennState Health
Milton S. Hershey Medical Center

Indocyanine Green (ICG)

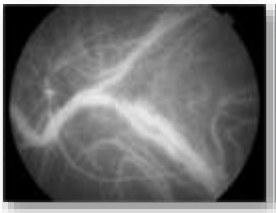

PennState Health
Milton S. Hershey Medical Center

Indocyanine Green (ICG)

- First used as a dye in the manufacture of Kodak Wratten filters.
- Used for cardiac output and liver function studies.
- Fluorescence occurs in the infrared range.
- Low efficiency of fluorescence compared with fluorescein.
- Large molecules don’t leak from the fenestrations in the choroidal vessels.

PennState Health
Milton S. Hershey Medical Center

Indocyanine Green (ICG)

- Peak excitation: 805nm
- Peak emission: 835nm

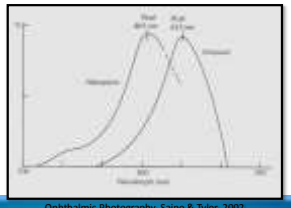

Ophthalmic Photography. Saine & Tyler, 2002.

PennState Health Milton S. Hershey Medical Center

ICG/Near Infrared Wavelengths

- Longer wavelengths allow better penetration through blood and RPE, allowing visualization of the choroidal vasculature.

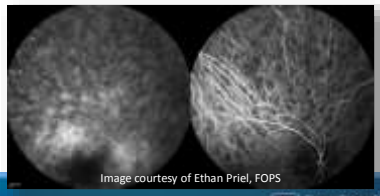

Image courtesy of Ethan Priel, FOPS

PennState Health Milton S. Hershey Medical Center

Scanning Laser Ophthalmoscope

PennState Health Milton S. Hershey Medical Center

Scanning Laser Ophthalmoscope

- The confocal scanning laser ophthalmoscope (cSLO) is an instrument that can be used for several imaging modalities including IR, red-free, IVFA, ICG, and fundus autofluorescence.

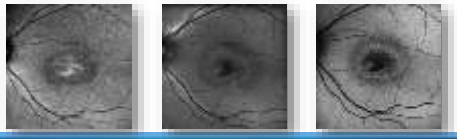

PennState Health Milton S. Hershey Medical Center

Clinical Confocal Imaging Devices

- Spectralis HRA
- Optos
- Nidek F-10
- Eidon

PennState Health Milton S. Hershey Medical Center

cSLO: Spectralis HRA

- 488 nm FA excitation and blue reflectance
- 790 nm ICG excitation
- 820 nm IR reflectance
- 565 nm green reflectance for MultiColor

Scanning Laser Ophthalmoscope

- A monochrome laser scans across the fundus in a raster pattern to illuminate and record successive elements of the retina, point-by-point at speeds up to 24 milliseconds.
- Multiple monochrome laser images taken simultaneously can be combined to create pseudo-color images.

PennState Health
Milton S. Hershey Medical Center

cSLO Pseudo Color

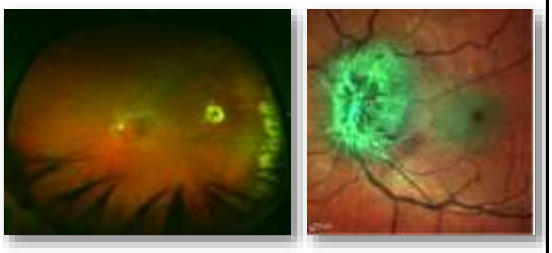

PennState Health
Milton S. Hershey Medical Center

Scanning Laser Ophthalmoscope

- A confocal pinhole blocks non image-forming light from reaching the sensor to minimize scatter and improve contrast.

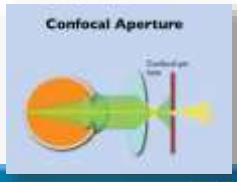

PennState Health
Milton S. Hershey Medical Center

Scanning Laser Ophthalmoscope

- The confocal pinhole reduces the effects of short wavelength scatter from cataracts or other media opacities.

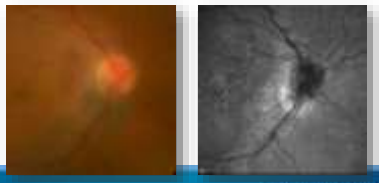

PennState Health
Milton S. Hershey Medical Center

Scanning Laser Ophthalmoscope

- The confocal pinhole reduces the effects of short wavelength scatter from cataracts or other media opacities.

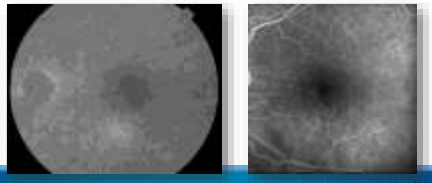

PennState Health
Milton S. Hershey Medical Center

cSLO Confocal Imaging

- Secondary effect of the confocal pinhole is a tonal shift when focus is adjusted.

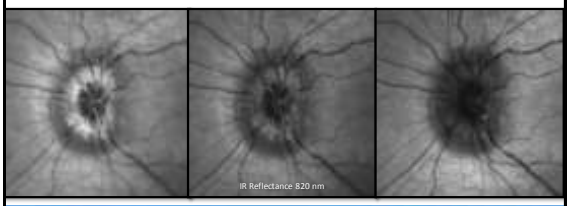

PennState Health
Milton S. Hershey Medical Center

Eye Tracking/Sampling

- Smoothes noise and increases exposure

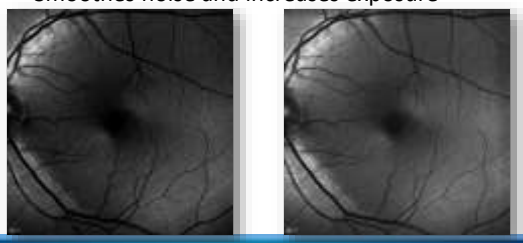

Fundus Autofluorescence (FAF)

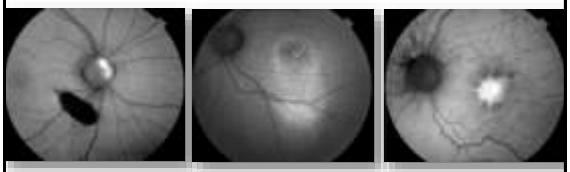

Fundus Autofluorescence (FAF)

- The term “autofluorescence” is used to distinguish fluorescence that can occur naturally from fluorescence that is derived from administration of fluorescent dyes.
- Optic nerve drusen, astrocytic hamartomas, lipofuscin pigments in the retina, and cataracts can exhibit natural fluorescence.

Fundus Autofluorescence (FAF)

- Lipofuscin is a fluorescent pigment that accumulates in the RPE as a metabolic byproduct of cell function.
- Lipofuscin deposition normally increases with age, but may also occur from RPE cell dysfunction or an abnormal metabolic load on the RPE.

Fundus Autofluorescence

- Fundus autofluorescence can be captured with either a modified fundus camera or cSLO.


PennState Health Milton S. Hershey Medical Center

FAF Findings

- The optic nerve, retinal blood vessels, and the fovea normally appear dark against a variable background of fluorescence from the RPE.
- The absence of the RPE at the optic nerve head causes it to appear dark.

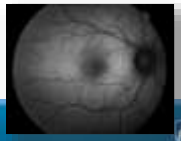

PennState Health Milton S. Hershey Medical Center

Findings/Interpretation

- Hyperfluorescence is a sign of increased lipofuscin accumulation, which may indicate degenerative changes or oxidative injury.
- Hypofluorescence usually indicates missing or dead RPE cells.

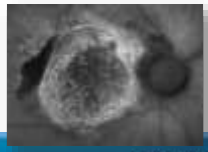

PennState Health Milton S. Hershey Medical Center

Documentary vs. Diagnosis

- Documentary:
  - Geographic atrophy
  - Pigmentary changes (RP, ICSC…)
- Diagnostic:
  - Early detection of bullseye/retinal toxicity
  - Buried disc drusen
  - ICSC activity/leakage?

PennState Health Milton S. Hershey Medical Center

Diagnostic Applications

- Geographic atrophy that appears as a "window defect" in fluorescein angiography will appear dark in autofluorescent imaging.

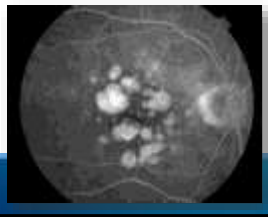


Diagnostic Applications

- The role of lipofuscin in macular degeneration isn't fully understood, but increased autofluorescence may precede development or progression of geographic atrophy in ARMD.

PennState Health Milton S. Hershey Medical Center

Diagnostic Applications

- Serial FAF imaging can be used to track progression of geographic atrophy.

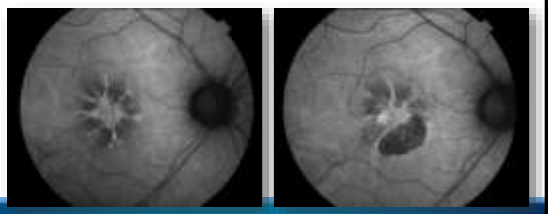

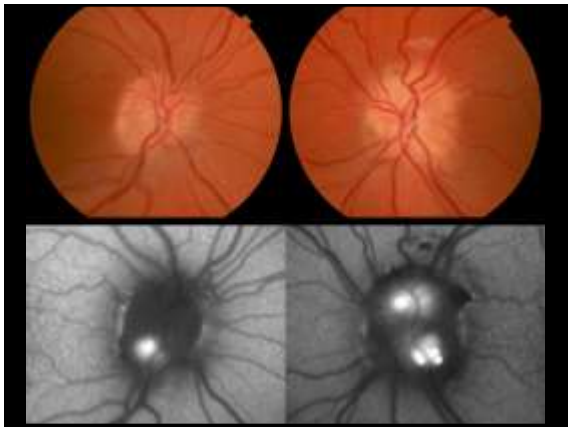

The Eye in Cross-Section

OCT Imaging

- Super luminescent diode light source
- Near-infrared wavelength: 820nm
- Analogous to ultrasound
- Time-of-flight delay (light echoes)
- Real time cross-sectional imaging
- Resolution measured in microns: >10

Cross-Sectional Imaging

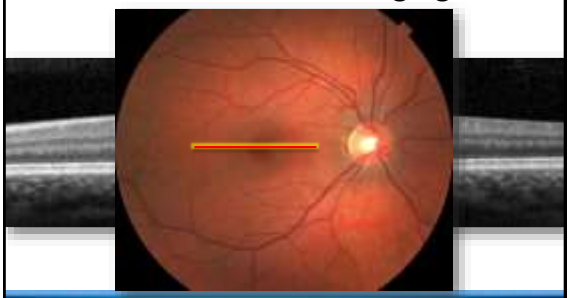

“Virtual Biopsy”

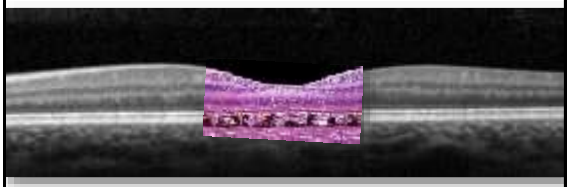

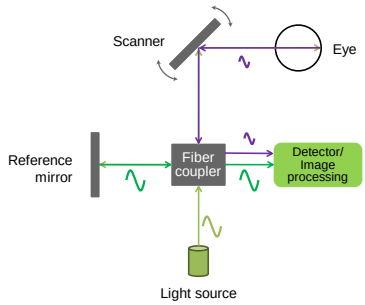

Cross-Sectional Imaging

- Measures both depth/distance and intensity of reflectivity.

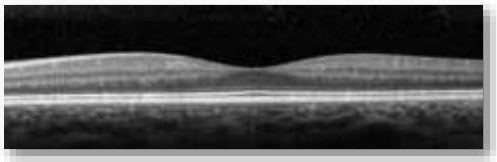

Anatomy of an OCT Scan

- Identifiable layers:
  - Posterior hyaloid
  - RNFL
  - Plexiform layers
  - Photoreceptors
  - RPE
  - Choroid

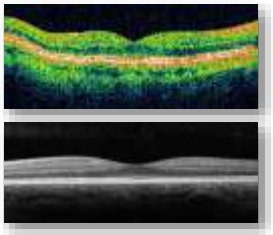

Anatomy of an OCT Scan

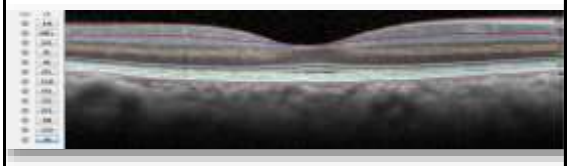

Common/Practical Use

- Line scans for structural changes.
- Line scans for detection of subretinal or intraretinal fluid.
- Volume scans for quantification of thickness or edema.

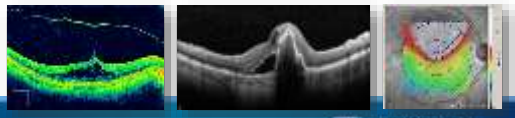

Common/Practical Use

- Optic nerve volume scan
  - Radial lines centered on cup
  - Cube Scan centered on disc
- RNFL scan
  - Circle around disc

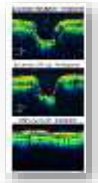



Anatomical Landmarks

Anatomical Landmarks

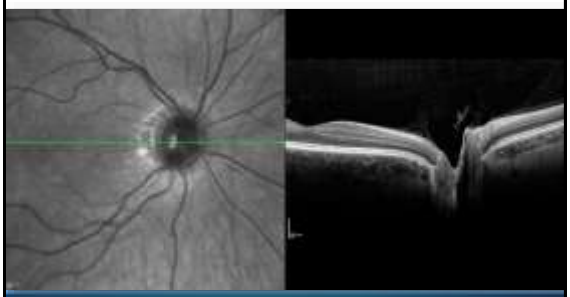

Anatomical Landmarks

- Anatomically, the fovea sits 5-7 degrees below the midpoint of the disc.

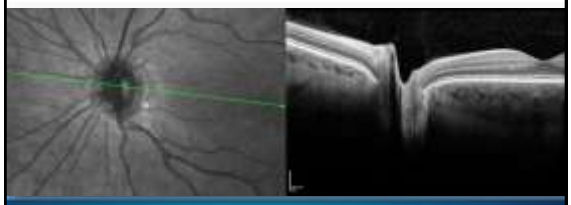

Anatomical Landmarks

Scanning Technique

- Pupils dilated?
- Head/chin straight and square.
- Encourage normal blinking pattern.
- Start with fast scan protocol.
- Optimize polarization ("Enhance").
- Don't forget focus.
- Move joystick (or mouse controls) to maximize signal "sweetspot".

Scanning Strategies

- Start with "Fast" or "HS" volume scans as a quick overview and watch for pathology during acquisition
  - Fast Macular Thickness or Macular Cube Scan

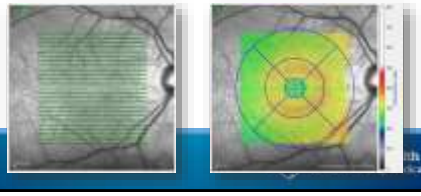

Scanning Strategies

- High-resolution horizontal & vertical single line scans centered on fovea.

PennState Health
Milton S. Hershey Medical Center

Scanning Strategies

- Free-scan or pan to detect subtle pathology.
- "Anchor" scan on known landmark.
- "Repeat" function restores settings from previous scans for consistency when doing custom scans.

PennState Health
Milton S. Hershey Medical Center

Fixation Issues

- Macular pathology often makes it difficult for patients to establish or maintain central fixation.

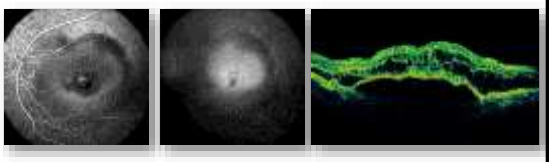

PennState Health
Milton S. Hershey Medical Center

Eccentric Fixation

- Let patient establish fixation.
- Capture scans on fixation first.
- Then try to center scan pattern over fovea or area of pathology & repeat:
  - click and drag the scan pattern over foveal depression (if visible).
  - "Anchor" scan on disc margin if depression isn't identifiable.

PennState Health
Milton S. Hershey Medical Center

"Anchor" Scan

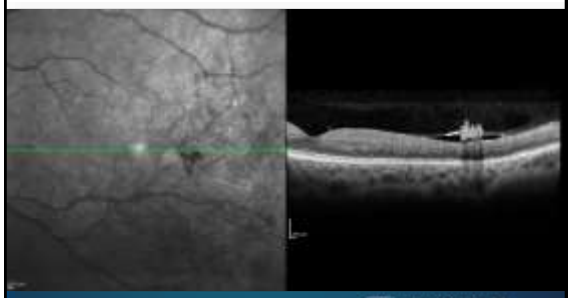

PennState Health
Milton S. Hershey Medical Center

"Anchor" Scan

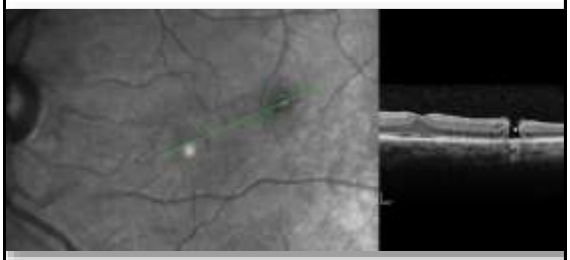

PennState Health
Milton S. Hershey Medical Center

"Anchor" Scan

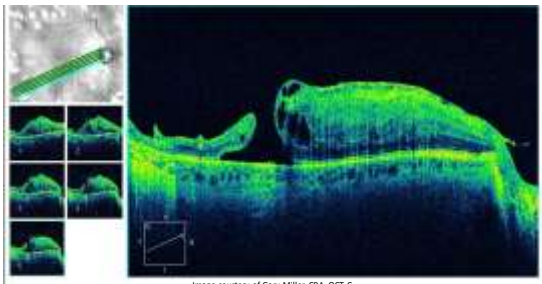

Image courtesy of Gary Miller, CRA, OCT-C

PennState Health
Milton S. Hershey Medical Center

"Anchor" Scan to Disc

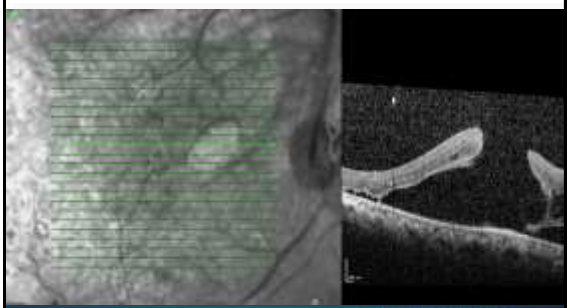

PennState Health
Milton S. Hershey Medical Center

"Anchor" Scan to Disc

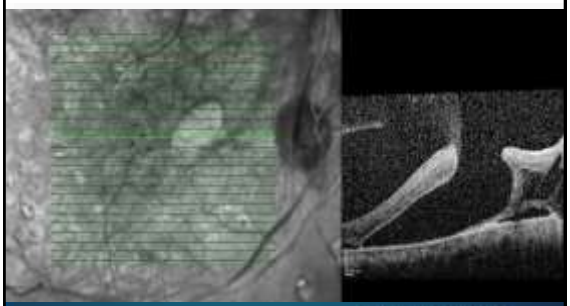

PennState Health
Milton S. Hershey Medical Center

What Defines a Quality Scan?

- Centered on target anatomy/pathology.
- Good edge-to-edge reflectivity.
- Good saturation/signal strength.
- As horizontally level as possible.
- Free from artifacts.

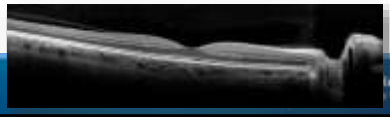

Signal Strength

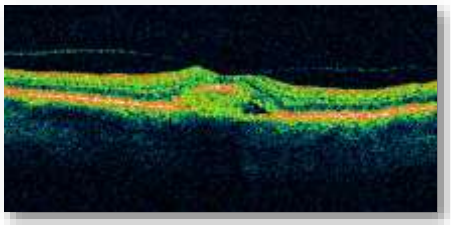

PennState Health
Milton S. Hershey Medical Center

Scan Quality

- Scan quality numbers (S/N ratio)
  - Cirrus Signal Strength of >5
  - Spectralis Quality Factor >25
  - Topcon Quality Factor >30-50
  - Optovue SSI >35-50 (different sources)
- Don't be a slave to the numbers!
  - How the image looks is more important than the quality number.

PennState Health
Milton S. Hershey Medical Center

Signal Strength

- Focus
- Polarization
- Z-offset
- Alignment within pupil
- Media opacities
- Tear film disruption
- Dirt/debris on objective

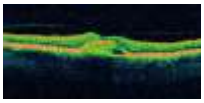

PennState Health
Milton S. Hershey Medical Center

Signal Strength/Focus

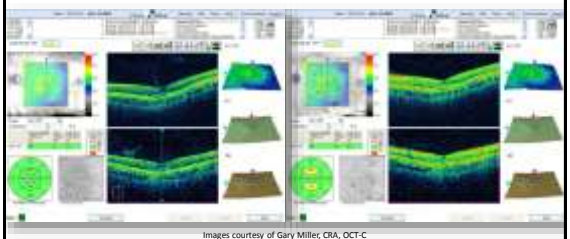

Images courtesy of Gary Miller, CRA, OCT-C

PennState Health
Milton S. Hershey Medical Center

Signal Strength/Focus

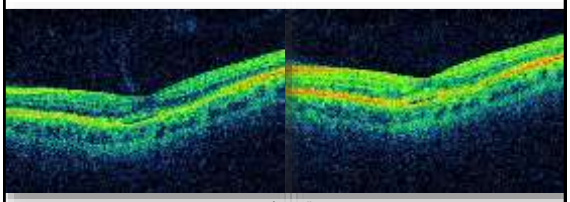

Images courtesy of Gary Miller, CRA, OCT-C

PennState Health
Milton S. Hershey Medical Center

Z-Offset/Signal Strength

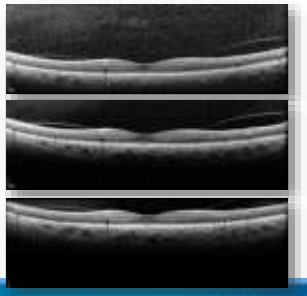

PennState Health
Milton S. Hershey Medical Center

Z-Offset/Signal Strength

ART: 100 frames, Q = 20

PennState Health
Milton S. Hershey Medical Center

Z-Offset/Signal Strength

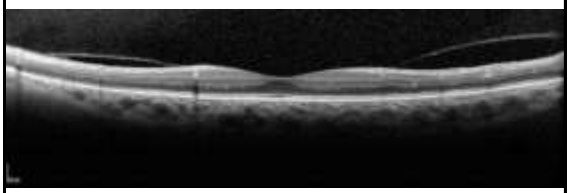

ART: 100 frames, Q = 28

PennState Health
Milton S. Hershey Medical Center

Z-Offset/Signal Strength

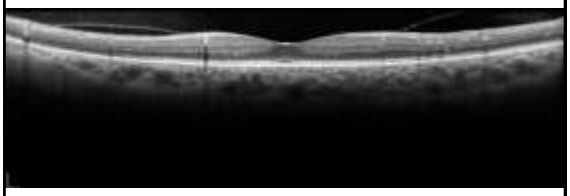

ART: 100 frames, Q = 36

PennState Health
Milton S. Hershey Medical Center

Signal Interference

- Signal strength can be adversely affected by several common eye conditions/findings
  - Cataract
  - Corneal opacities
  - Floaters/Asteroids
  - Intraocular blood
  - Astigmatism
  - Poorly centered IOL/small capsulotomy

PennState Health
Milton S. Hershey Medical Center

Media Opacities

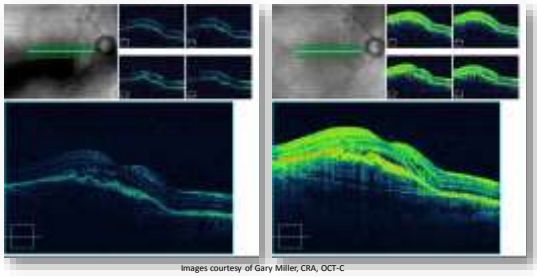

Images courtesy of Gary Miller, CRA, OCT-C

PennState Health
Milton S. Hershey Medical Center

Signal Interference

- A major culprit is dry eye or inadequate tear film.
- Tear film can be disturbed by several routine eye examination procedures:
  - applanation tonometry.
  - diagnostic contact lens exam.
  - gonioscopy.

PennState Health
Milton S. Hershey Medical Center

Signal Interference

- Whenever possible, perform OCT before any procedures that can compromise integrity of the tear film.

PennState Health
Milton S. Hershey Medical Center

Signal Interference

- Whenever possible, perform OCT before any procedures that can compromise integrity of the tear film.

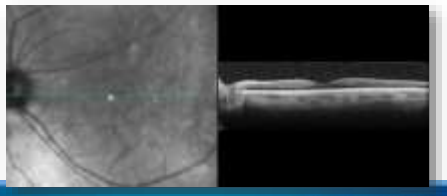

PennState Health
Milton S. Hershey Medical Center

Before Artificial Tears

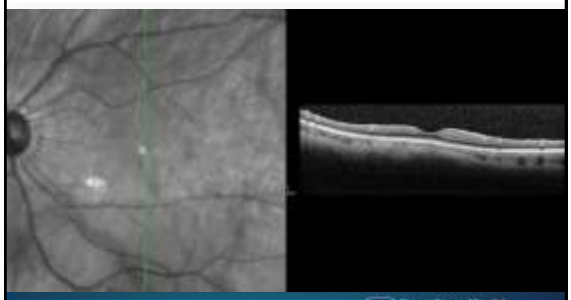

PennState Health
Milton S. Hershey Medical Center

After Artificial Tears

PennState Health
Milton S. Hershey Medical Center

OCT Angiography (OCT-A)

- Samples same area of the retina after correcting for eye movement.
- Detects motion (blood flow).
- Depth encoded en-face map of blood flow.

Images courtesy of Darrin Landry, CRA, OCT-C

PennState Health
Milton S. Hershey Medical Center

Tips for OCT

- "Flirt" with the top of the scan window.
- Make sure tear film is intact/refreshed.
- Look for good edge-to-edge illumination & saturation.
- "Anchor" scans to midpoint of optic disc margin if unable to detect fovea.
- "Anchor" scans to recognizable anatomy if scanning atypical areas or angles.

PennState Health
Milton S. Hershey Medical Center

The Spectrum of Retinal Imaging

- Fundus Photography
- Monochromatic Photography
- Fluorescein Angiography
- ICG Angiography
- Scanning Laser Ophthalmoscopy
- Fundus Autofluorescence
- Optical Coherence Tomography

PennState Health
Milton S. Hershey Medical Center

Thank You!

- Questions?
  timbennett@eye-pix.com
- Handouts:

www.eye-pix.com

PennState Health
Milton S. Hershey Medical Center

The Spectrum of Retinal Imaging

Timothy J. Bennett, CRA, FOPS, OCT-*C*
Penn State Eye Center
Hershey, PA

PennState Health
Milton S. Hershey Medical Center

Fundus Photography

- Fundus photographs are used for clinical documentation, teaching, retinal screening, remote consultation, and clinical trials.
- Some retinal details may be easier to identify in stereoscopic fundus photographs compared with direct examination.
- Serial photographs are commonly used to track disease progression.

PennState Health
Milton S. Hershey Medical Center

Fundus Camera

- The modern fundus camera is a horizontally mounted instrument with an internal electronic flash and an attached 35mm camera or digital sensor.

PennState Health
Milton S. Hershey Medical Center

SD Inversion

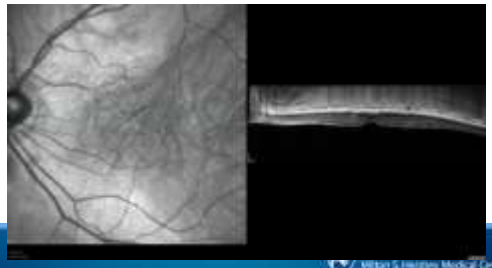

Milton S. Hershey Medical Center

Inversion Artifacts

- Common artifact in SD-OCT

Inversion Artifacts

- Pathology is “too tall” for scan window
  - > 2mm
  - High myope, RD, traction, etc.
- Too close to eye/top of scan window.
- Only part of image inverts.
- Image may partially or completely flip for a few frames during sampling.

PennState Health
Milton S. Hershey Medical Center

Scanning artifacts

- Placement of scan image within scan window (z-offset) is very important for minimizing inversion artifacts.
- Can be a trade-off between maximum signal strength and partial inversion.

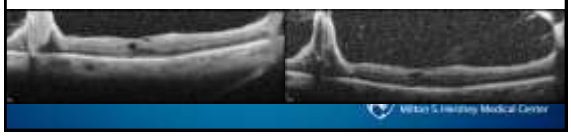

Sample "Painting"

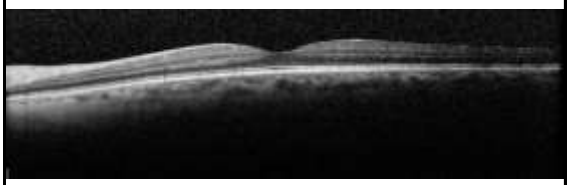

Sample "Painting"

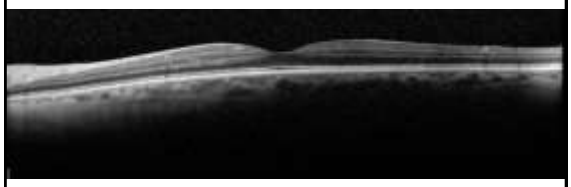

Sample "Painting"

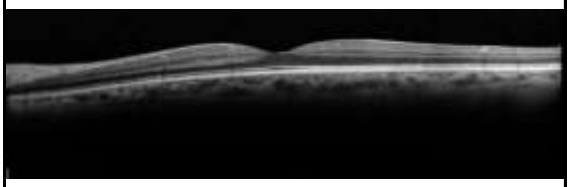

Sample "Painting"

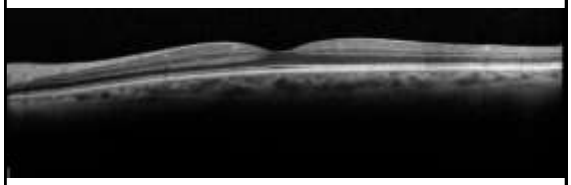

Sample "Painting"

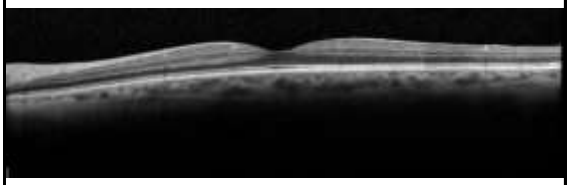

Sample “Painting”

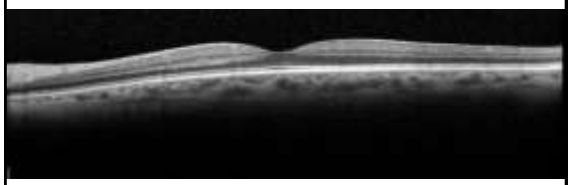

Sample “Painting”

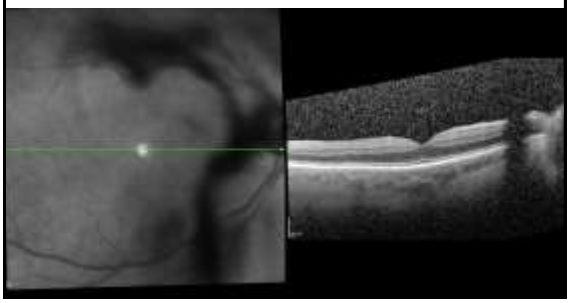

Sample “Painting”

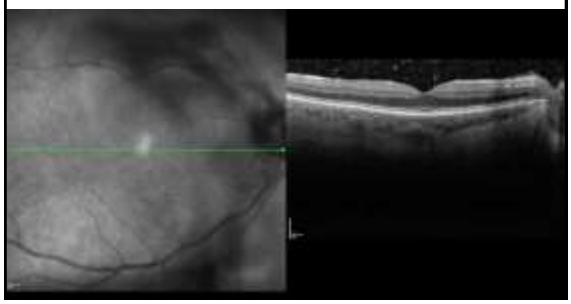

Sample “Painting”

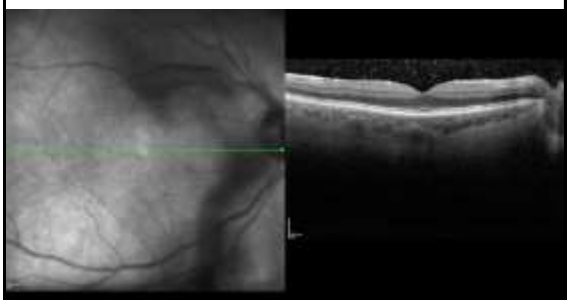

Sample “Painting”

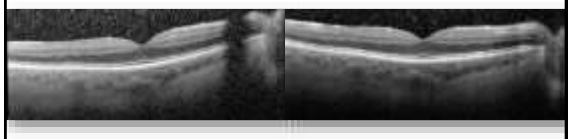

Enhanced Depth Imaging (EDI)

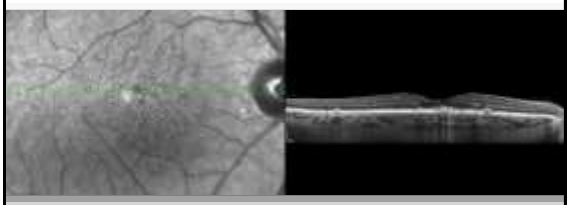

Enhanced Depth Imaging (EDI)

PennState Health
Milton S. Hershey Medical Center

Enhanced Depth Imaging (EDI)

PennState Health
Milton S. Hershey Medical Center

Enhanced Depth Imaging (EDI)

PennState Health
Milton S. Hershey Medical Center

Enhanced Depth Imaging (EDI)

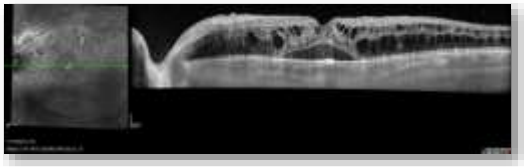

PennState Health
Milton S. Hershey Medical Center

EDI/FDI

- Start sampling image and engage EDI feature about half way through sample.

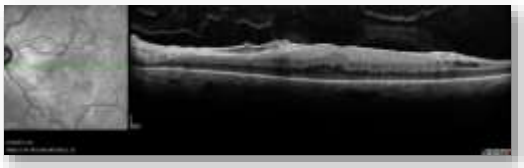

PennState Health
Milton S. Hershey Medical Center

EDI/FDI

- Start sampling image and engage EDI feature about half way through sample.

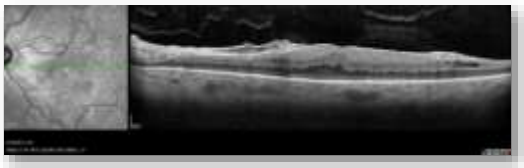

PennState Health
Milton S. Hershey Medical Center

Inversion Artifacts

- Pathology is "too tall" for scan window
  - > 2mm
  - High myope, RD, traction, etc.
- Too close to eye/top of scan window.
- Only part of image inverts.
- Image may partially or completely flip for a few frames during sampling.

PennState Health
Milton S. Hershey Medical Center

Inversion Artifacts

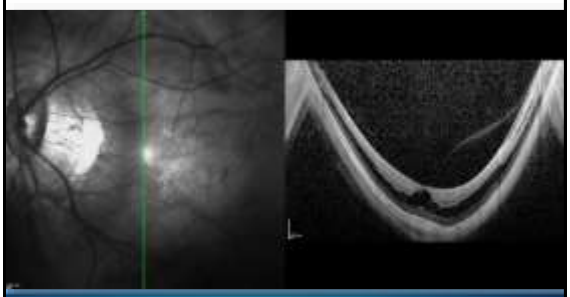

PennState Health
Milton S. Hershey Medical Center

Inversion Artifacts

PennState Health
Milton S. Hershey Medical Center

Inversion Artifacts

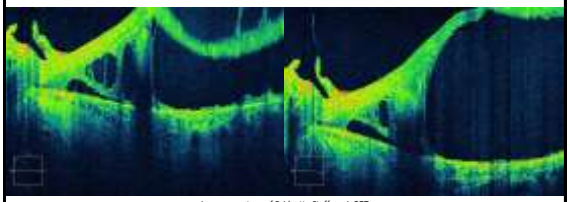

Images courtesy of Bridgette Staffaroni, COT

PennState Health
Milton S. Hershey Medical Center

EDI to Eliminate Inversion

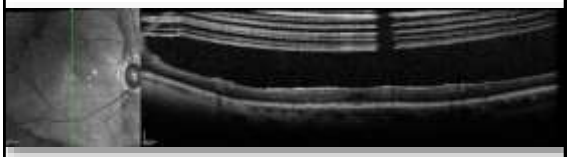

PennState Health
Milton S. Hershey Medical Center

EDI to Eliminate Inversion

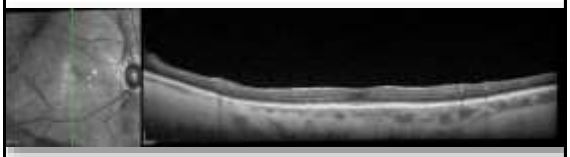

PennState Health
Milton S. Hershey Medical Center

EDI to Eliminate Inversion

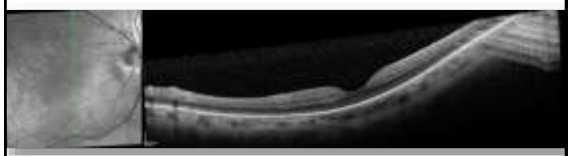

PennState Health
Milton S. Hershey Medical Center

EDI to Eliminate Inversion

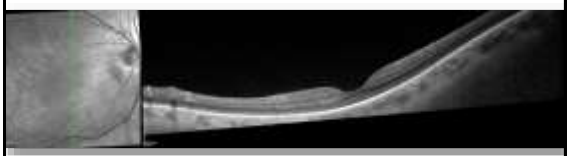

PennState Health
Milton S. Hershey Medical Center

To Blink or Not to Blink?

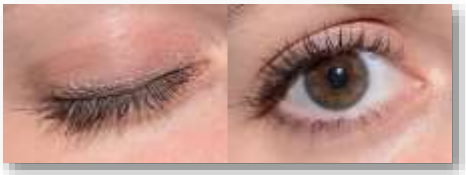

PennState Health
Milton S. Hershey Medical Center

Oogies on My Lens!

PennState Health
Milton S. Hershey Medical Center

To Blink or Not to Blink?

PennState Health
Milton S. Hershey Medical Center

To Blink or Not to Blink?

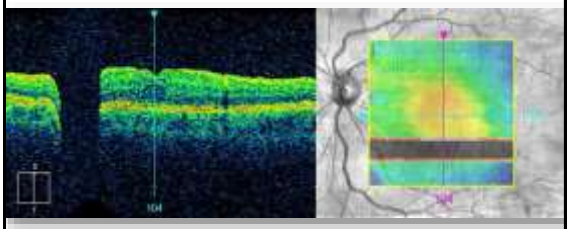

PennState Health
Milton S. Hershey Medical Center

Signal Interference

- Frequent blinking and/or instillation of artificial tears often improves image quality.

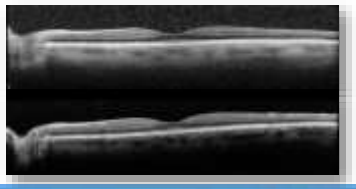

Oogies on My Lens!

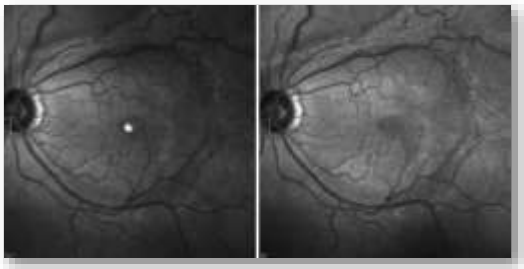

Review: Tips for Fundus Photography

- Set the camera eyepiece correctly
  - Ignore the diopter numbers.
  - Relax accommodation to distance.
  - Make sure the reticle and the retina appear sharp at the same time.
- Use green filter to focus on vessels or with photophobic pt.

Review: Tips for Fundus Photography

- Maintain consistent technique from visit to visit with serial imaging.
- Facilitate best possible dilation (mydriatic or non-myd).

Review: Tips for OCT

- Head/chin straight and square
  - Important for consistent alignment of serial scans.
  - Helps proper anatomic alignment when using horizontal scan patterns.
- Encourage normal blinking pattern
  - It's our job to capture images between blinks!
- Use artificial tears on patients with DES or compromised tear film.

Review: Tips for OCT

- "Flirt" with the top of the scan window.
- Look for good edge-to-edge illumination & saturation.
- "Anchor" scans to midpoint or bottom of optic disc margin if unable to detect fovea.
- "Anchor" scans to recognizable anatomy if scanning atypical areas or angles.

Thank You!

- Questions?
  timbennett@eye-pix.com
- Handouts:

http://eye-pix.com/event/lecture-tips-and-tactics-for-retinal-imaging/

PennState Health
Milton S. Hershey Medical Center

Common Uses of OCT

- Line scans for structural changes
- Line scans for detection of subretinal or intraretinal fluid
- Volume scans/maps for measurement of thickness or swelling

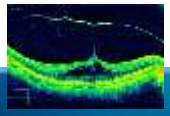
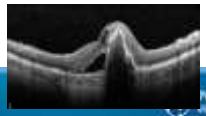


Fundus Camera

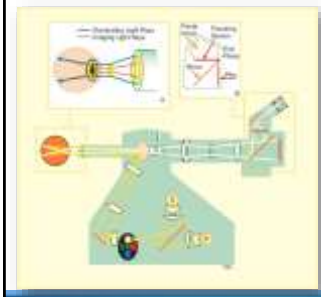


PennState Health
Milton S. Hershey Medical Center

Fundus Photography

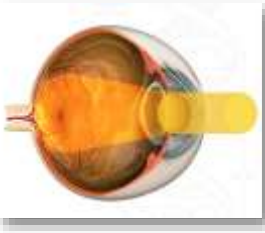


PennState Health
Milton S. Hershey Medical Center